

PAPER • OPEN ACCESS

## Relationships between broiler final weights and histomorphometric parameters of certain segments of the intestine

To cite this article: Branislav M. Baltic *et al* 2021 *IOP Conf. Ser.: Earth Environ. Sci.* **854** 012006

View the [article online](#) for updates and enhancements.

### You may also like

- [Wooden breast – a novel myopathy recognized in broiler chickens](#)  
M Baltic, A Rajcic, M Laudanovic et al.
- [Effects of the probiotic \*Bacillus subtilis\* and \*Enterococcus faecium\* on growth performance, hematological values and small intestinal morphology of broiler chicks](#)  
N H Aziz, Z O H Ahmed, A H Hassan et al.
- [Effects of feed form on small intestine histomorphology of broilers](#)  
B Ariyadi, S Sudaryati, S Harimurti et al.



The Electrochemical Society  
Advancing solid state & electrochemical science & technology

242nd ECS Meeting

Oct 9 – 13, 2022 • Atlanta, GA, US

**Extended abstract submission deadline: April 22, 2022**

Connect. Engage. Champion. Empower. Accelerate.

**MOVE SCIENCE FORWARD**



Submit your abstract



# Relationships between broiler final weights and histomorphometric parameters of certain segments of the intestine

**Branislav M. Baltic<sup>1</sup>, Ivana Brankovic Lazic<sup>1</sup>, Boris Mrdovic<sup>1</sup>, Vesna Djordjevic<sup>1</sup>, Radmila Markovic<sup>2</sup>, Radmila Mitrovic<sup>1</sup> and Jelena Janjic<sup>2</sup>**

<sup>1</sup> Institute of Meat Hygiene and Technology, Kacanskog 13, Belgrade, Republic of Serbia

<sup>2</sup> University of Belgrade, Faculty of Veterinary Medicine, Bulevar oslobodjenja 18, Belgrade, Republic of Serbia

E-mail: [branislav.baltic@inmes.rs](mailto:branislav.baltic@inmes.rs)

**Abstract:** The aim of this study was to determine relationships between final mass of broilers and the histomorphological properties of individual segments of the gastrointestinal tract. This is confirmed by the obtained results, which indicate a strong and significant correlation between compared parameters. A strong significant ( $p < 0.05$ ) correlation ( $r = 0.866$ ) was found between the broiler final weight and the duodenal villus length, and between the broiler final weight and the caecal villus length ( $r = 0.918$ ). Correlation between the broiler final weight and the duodenal villus width ( $r = 0.841$ ), as well the caecal villi width ( $r = 0.918$ ) was strongly significant ( $p < 0.05$ ). Between the crypt depths in caecum correlation was medium and significant ( $r = 0.701$ ,  $p < 0.05$ ). It was determined that between the broiler final weights and the ratio of villus length and crypt depth there is a significant medium correlation ( $r = 0.736$ ,  $p < 0.05$ ). A strong ( $r = 0.924$ ) significant ( $p < 0.05$ ) correlation was found between the broiler final weight and the ratio of villus length and caecal crypt depth. Between final mass of broilers and other histomorphological properties of individual segments of intestine there was no significant correlation.

## 1. Introduction

In order to improve genetic potential of highly selected broiler hybrids (Cobb, Ross), appropriate conditions of health care, accommodation, and especially nutrition are required. The gastrointestinal tract (GIT) of poultry has not only the function of digestion and absorption of nutrients, but it is also a metabolic and immunological organ, which serves to limit the presence of harmful agents, primarily bacteria and protozoa (coccidia and intestinal parasites), in the GIT. Maintaining a balanced ratio of harmful and useful microorganisms (eubiosis) in the poultry GIT has special importance for its health, and thus the health of the animals, and hence the production results and economy of meat production. Antibiotics (growth promoters) were used for the protection and health of animals' GIT. Their use has caused two negative phenomena, one of which is the finding of antibiotic residues in meat (eggs), and the other, certainly was a much more serious phenomenon, bacterial resistance, which is why their use is now forbidden. In order to preserve animal health in modern intensive poultry production, alternatives to antibiotics are required. As an alternative to antibiotics, medium-chain fatty acids (MCFAs) are used,



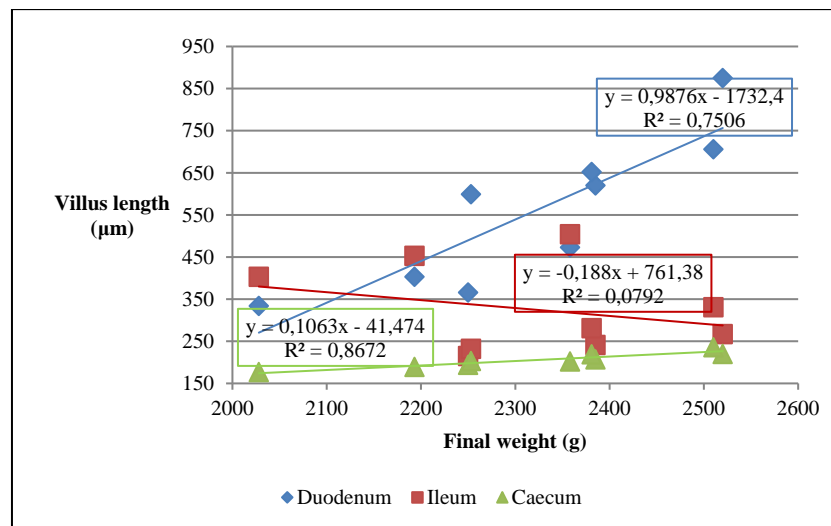
singly or as two or more MCFAs in poultry diets. One of such commercial products, Aromabiotic®, is recommended in poultry nutrition. The use of MCFA in broiler nutrition contributes to preserving the health of the GIT, and thus to better production results (higher final body weight, higher growth, and better feed conversion). The aim of this study was to examine the correlation between the final mass of broilers and the histomorphological properties of individual segments of the gastrointestinal tract.

## 2. Materials and methods

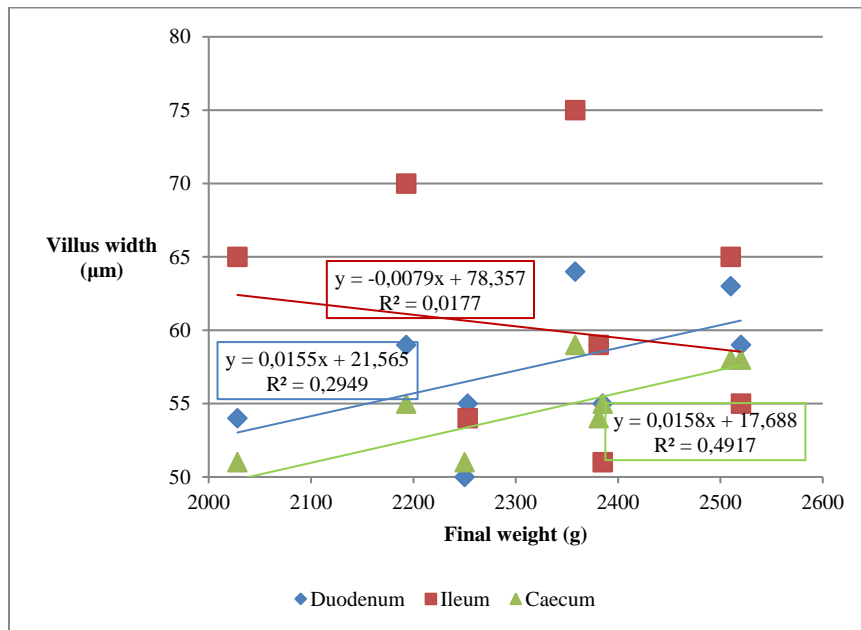
The conditions of keeping and feeding broilers are described in previous works [1, 2]. Birds were randomly assigned to one of three dietary treatments (control and two experimental groups), each having six replicates (ten birds in each replicate). Immediately after the animal slaughter, parts of the small intestine (duodenum and ileum) and caecum were collected for histological analyses from each group. The tissue samples were fixed in 10% buffered formalin saline, then dehydrated by immersing through a series of alcohols and embedded in paraffin by standard technique. Sections 5 to 8 µm in thickness were stained with Mayer's haematoxylin and eosin (HE) method [3]. Morphometric examinations of the villi length and width, as well as the crypt depth, were carried out using an ocular micrometer 1:100 [4]. Pearson's correlation was used to determine the correlation between the final mass of broilers and the histomorphometric properties of individual segments of the broiler gastrointestinal tract. Statistical analysis of the data and presentation of the results obtained was conducted using the Microsoft Excel 2013 and GraphPad Prism software, version 8.00 for Windows (GraphPad Software, San Diego, California USA, [www.graphpad.com](http://www.graphpad.com)).

## 3. Results and Discussion

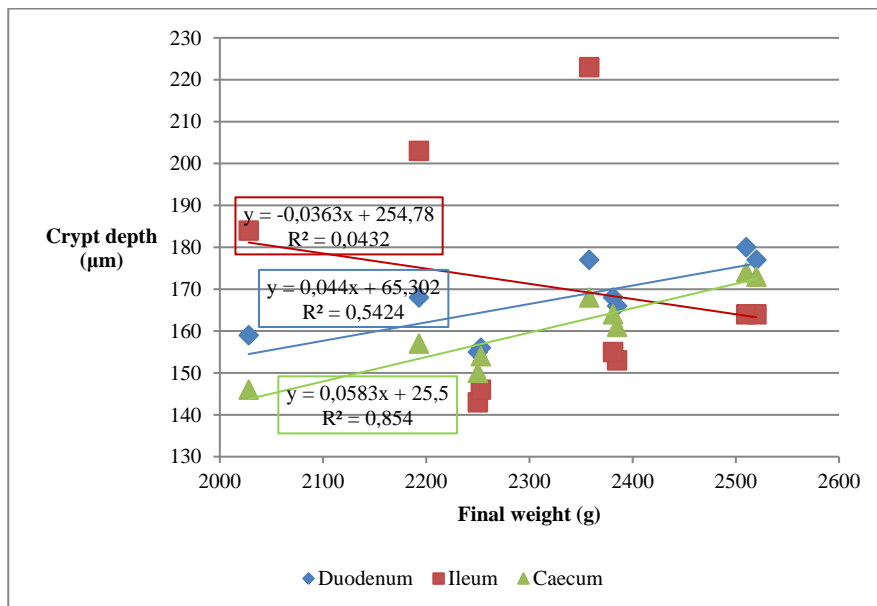
Final body weight, average daily gain and feed conversion are most often used as indicators of production results in poultry nutrition [5,6]. These parameters can be correlated with the histomorphometric properties of the GIT. The correlation between the broiler final weight (g) and the histomorphometric properties of individual segments of the broilers' digestive tract are present in Figures 1 to 5.



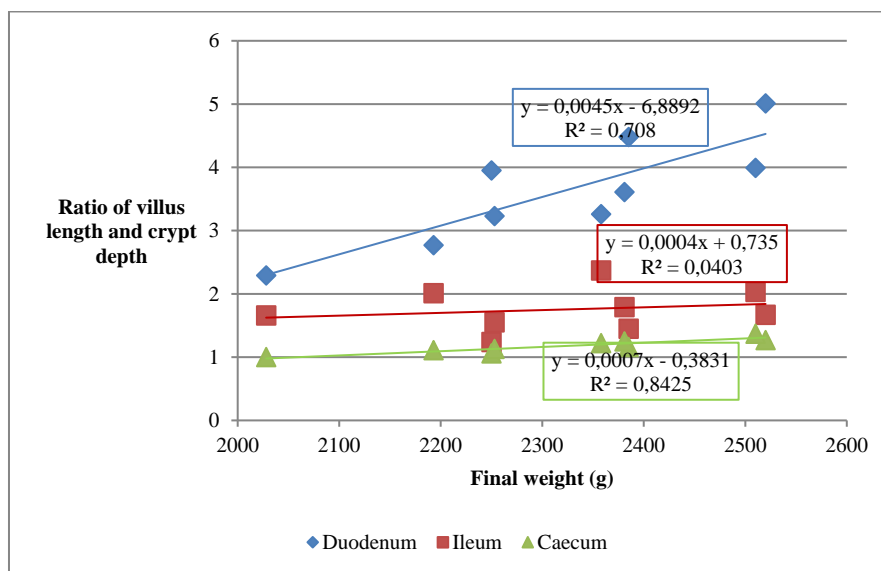
**Figure 1.** Correlation between the broiler final weight (g) and villus length (µm) in broilers



**Figure 2.** Correlation between the broiler final weight (g) and villus width (µm) in broilers



**Figure 3.** Correlation between the broiler final weight (g) and the crypt depth of the intestinal villi (µm) in broilers



**Figure 4.** Correlation between the broiler final weight (g) and the ratio of villus length to crypt depth of intestinal villus in broilers

The correlations and significance of differences between the broiler final weight and histomorphometric parameters of individual segments of the intestine are present in Table 1. A strong significant ( $p < 0.05$ ) correlation dependence ( $r = 0.866$ ) was found between the broiler final weight and the duodenal villus length. Also, a significant ( $p < 0.05$ ) strong correlation ( $r = 0.918$ ) was found between the broiler final weight and the caecal villus length. There was a weak negative correlation dependence ( $r = -0.281$ ), which was not significant ( $p > 0.05$ ), between the broiler final weight and the ileal villus length. A strong ( $r = 0.841$ ) statistically significant ( $p < 0.05$ ) correlation dependence was found between the broiler final weight and the duodenal villus width, as well as a strong significant ( $p < 0.05$ ) correlation ( $r = 0.918$ ) between the final body weight of the broiler and the caecal villi width. There was no correlation dependence between the ileal villus width and the broiler final weight ( $r = 0.201$ ). A medium correlation dependence was found between the crypt depths in duodenum, i.e. the crypt depth in caecum ( $r = 0.543$ , duodenum, or  $r = 0.701$ , caecum). The correlation dependence ( $r = 0.543$ ) between the broiler final weight and the duodenal crypt depth was not significant ( $p > 0.05$ ), while the correlation ( $r = 0.701$ ) between the broiler final weights and the caecal crypt depths was significant ( $p < 0.05$ ). Broiler final weight and the ratio of villus length to crypt depth, exhibited a significant ( $p < 0.05$ ) medium correlation ( $r = 0.736$ ). A strong ( $r = 0.924$ ) significant ( $p < 0.05$ ) correlation was found between the broiler final weight and the ratio of villus length to caecal crypt depth. There was no correlation dependence ( $r = -0.208$ ) between the broiler final weight and the ratio of villus length to ileum crypt depth.

**Table 1.** Correlation dependence and significance of the difference between the broiler final weight and histomorphometric parameters of individual intestinal segments

Histomorphometric parameter	Intestine segment	Correlation coefficient (r)	Interpretation of correlation dependence*	Significance of difference
Intestinal villus length	Duodenum	0.866	Strong	$p < 0.05$
	Ileum	- 0.281	Weak	ns

	Caecum	0.930	Strong	p<0.05
	Duodenum	0.841	Strong	p<0.05
Intestinal villus width	Ileum	0.201	No correlation	ns
	Caecum	0.918	Strong	p<0.05
	Duodenum	0.543	Medium	ns
Intestinal crypt depth	Ileum	- 0.133	No correlation	ns
	Caecum	0.701	Medium	p<0.05
	Duodenum	0.736	Medium	p<0.05
The ratio of villus length /crypt depth	Ileum	- 0.208	No correlation	ns
	Caecum	0.924	Strong	p<0.05

Legend: ns – not significant; \* Source: Colton, 1974 [7]

The efficacy of MCFA use is based on their influence on the morphological properties and on the microbiota of the GIT. At beginning of fattening, there is a rapid physical and functional development of the GIT and there are morphological changes in the duodenum, jejunum, and ileum. Thus, in the first few days, changes in the villus length are especially pronounced, and in two to three days, crypts are formed. With the change of morphological properties, the ability to absorb nutrients continuously increases. Also, the activity of pancreatic enzymes, which was observed even before hatching, increases in the first days of broiler life [8]. Intestinal villi and crypts are units of epithelium that allow the absorption of nutrients and are renewed every four to five days [9]. Greater cell regeneration and a lower degree of enterocyte apoptosis, or both, contribute to longer villus length and even greater surface area of the mucosa, which result in greater nutrient resorption. The degree of absorption is particularly important for protein absorption since 20 to 40% of the protein is synthesized in the GIT [10,11]. Morphometric examinations of the GIT (duodenum and jejunum) are also important because fats and other nutrients are absorbed in these parts of the GIT. The villi are covered with enterocytes that form in the crypts of Lieberkühn, from where they migrate to the top of the villi. The migration of enterocytes to the top of the villi and their loss due to apoptosis are in balance in a healthy animal, and the loss of enterocytes occurs as a consequence of numerous pathogenic bacteria, which ultimately causes an increase in the crypt depth. More favorable morphological properties, i.e., an increase in the villus length and width of the intestinal segments, especially the duodenum and caecum, lead to an increase in the resorptive surface of these intestinal segments. The reduced depth of the crypts and the altered ratio of the villus length and the crypt depth indicate a reduced replacement of enterocytes, i.e. a reduced need for the formation of new cells. Growth of new enterocyte cells and maintenance of the normal structure of the GIT requires significantly more energy and an increased need for proteins. In the phase of intensive growth in energy demand, they make up 25% of the needs, i.e. 12% of the protein needs out of the total needs [12, 13, 14]. With increasing broiler age, the crypt depth and the number of enterocytes per cross section of the villi increase. However, the number of villi per unit area, especially in the duodenum, decreases [15]. The density of enterocytes in different segments of the intestine does not change with broiler age. Maximum digestibility and resorption of nutrients and, thus, the impact on production results, are conditioned by the size of the intestinal surface and with the optimal functional maturity of enterocytes [16]. Adding MCFA to the broiler's feed leads to a significant increase in the villus length and width and, thus, to an increase in the absorption surface area of the duodenal, ileum, and caecum epithelia in forty-day-old broilers [17, 18, 19, 20, 21]. Also, the addition of MCFA increases the villus length and the crypt depth, but only in the ileum. Lesson et al. [22] and Panda et al. [23] report that MCFA in broiler nutrition increases the villus length and the crypt depth in the duodenum, from

which it can be concluded that this can greatly help young individuals in the development of the digestive tract. This was confirmed in another study as well [24]. It has also been confirmed that the use of MCFA in broiler feed leads to increased villus length and increased enzyme production, better digestion, increased resorption area, and, thus, better absorption of food nutrients [25]. MCFAs reduce intestinal colonization of pathogens and the occurrence of infections, reduce the frequency of inflammatory processes in the mucosa, increase villus length and secretion, and increase digestion and resorption of nutrients [26].

#### 4. Conclusion

Broiler feed with added MCFA contributes not only to the health preservation of the GIT, but also significantly affects strong correlations between broiler final weight and duodenal and caecal villus length, duodenal and caecal villus width, and caecal ratio of villus length/crypt depth. Significant medium correlation was determined between broiler final weight and caecal crypt depth, and also duodenal ratio of villus length/crypt depth. The results obtained showing the correlation between broiler final weight and histomorphometric parameters of individual segments of the intestine indicate the justifiable use of MCFA in broiler nutrition.

#### Acknowledgments

This study was supported by the Ministry of Education, Science and Technological Development of the Republic of Serbia, according to the provisions of the Contract on research financing in 2021 (No 451-03-9/2021-14/200050 dated 05.02.2021).

#### References

- [1] Baltić B, Ćirić J, Šefer D, Radovanović A, Đorđević J, Glišić M, Bošković M, Baltić M Ž, Đorđević V and Marković R 2018 *S. Afr. J. Anim. Sci.* **48** (5) 885–96
- [2] Baltic B M, Janjic J, Lazic Brankovic I, Mrdovic B, Ciric J, Markovic R and Mitrovic R 2019 In *IOP Conference Series: Environ. Earth Sci.* **333** 1 p 012045
- [3] Scheuer J P and Chalk T B 1986 *Clinical tests: Histopathology* (Netherlands: Wolfe Medical Publ. Ltd)
- [4] Djolai M, Somer L, Damjanov D, Hadnadjev L and Krnojelac D 1998 *Folia Anatomica* **26** 56–7
- [5] Baltić M Ž, Marković R and Đorđević V 2011 *Meat Technol.* **52** (1) 154–9
- [6] Glamoclija N, Sevic K, Baltic B, Boskovic M, Janjic J, Djordjevic V and Markovic R 2016 *Meat Technol.* **57** (2) 89–94
- [7] Colton T 1974 *Statistics in Medicine* (New York: Little Brown and Company) **189** p 218
- [8] Sclan D 2001 *World Poult. Sci. J.* **57** (4) 415–28
- [9] Günther C, Neumann H, Neurath M F and Becker C 2013 *Gut* **62** (7) 1062–71
- [10] Chwen LT, Foo H L, Thanh N T and Choe D W 2013 *Asian-Australas. J. Anim. Sci.* **26** 5 p 700
- [11] Zentek J, Buchheit-Renko S, Ferrara F, Vahjen W, Van Kessel A G and Pieper R 2011 *Anim. Health Res. Rev.* **12** (1) 83–93
- [12] Loddi M M, Moraes V M, Nakaghi L S O, Tucci F M, Hannas M I and Arika J A 2004 *Proceeding of the 20th Annual Symposium Suppl.* **1** 45
- [13] Croom J, Edens F W and Ferket P R 2000 In *Proceedings of the 27th Annual Carolina Poultry Nutrition Conference*. Raleigh NC: Carolina Feed Industry Association, Research Triangle Park 65–73
- [14] Marković R, Šefer D, Krstić M and Petrujkić B 2009 *Arch Med Vet* **41** (2) 163–9
- [15] Uni Z, Tako E, Gal-Garber O and Sklan D 2003 *Poult. Sci.* **82** (11) 1747–54
- [16] Cera K R, Mahan D C, Cross R F, Reinhart G A and Whitmoyer R E 1988 *Sci. J. Anim. Sci.*, **66** 574–84
- [17] Garcia V, Catala-Gregori P, Hernandez F, Megias M D and Madrid J 2007 *J Appl Poult Res* **16** (4) 555–62
- [18] Kim S A and Rhee M S 2016 *Food Control* **60** 447–54

- [19] Tactacan G B, Rodriguez-Lecompte J C and House J D 2012 *Poult. Sci.* **91** (1) 121–8
- [20] Abudabos AM, Alyemni AH, Swilam EO and Al-Ghadi M 2017 *Pak J Zool* **49** 1989–95
- [21] Sultan A, Ullah T, Khan S and Khan R U 2015 *Pak. J. Zool.* **47** 3
- [22] Leeson S, Namkung H, Antongiovanni M and Lee E H 2005 *Poult. Sci.* **84** (9) 1418–22
- [23] Panda A K, Rama R, Rao S V, Raju M V L N and Shyam G S 2009 *Asian-Austral. J. Anim. Sci.* **22** 1026–31
- [24] Adil S, Banday T, Bhat G A, Mir M S and Rehman M 2010 *Vet. Med. Int.* DOI 10.4061/2010/479485
- [25] Awad W A, Chareeb K, Abdel-Raheem S and Böhm J 2009 *Poult. Sci.* **88** 49–56
- [26] Khan S H and Iqbal J 2016 *J. Appl. Anim. Res.* **44** (1) pp 359–69