



ELSEVIER

Clinical Research

A Novel Antegrade Approach for Simultaneous Carotid Endarterectomy and Angioplasty of Proximal Lesions in Patients with Tandem Stenosis of Supraaortic Arch Vessels

Djordje Radak,^{1,2} Slobodan Tanaskovic,^{1,2} Dragan Sagic,^{2,3} Zelimir Antonic,³ Predrag Gajin,^{1,2} Srdjan Babic,^{1,2} Mihailo Neskovic,^{1,2} Predrag Matic,^{1,2} Vladimir Kovacevic,³ Dragoslav Nenezic,^{1,2} and Nenad Ilijevski,^{1,2} Belgrade, Serbia

Background: To date, all published studies analyzing simultaneous treatment of carotid and proximal atherosclerotic lesions are describing retrograde approach and several technical variations. In the presented study, for the first time, antegrade approach is described for simultaneous carotid endarterectomy (CEA) and associated brachiocephalic trunk (BCT) or common carotid artery (CCA) angioplasty in the hybrid operating room.

Methods: From January 2012 till January 2016, antegrade hybrid procedures were performed in 18 patients. All patients were admitted to our institute for elective supraaortic arch multidetector computed tomography angiography when significant simultaneous proximal and distal supraaortic arch lesions were revealed. After surgical exposure of carotid arteries, proximal lesions were crossed by antegrade approach. Prior to stent placement, internal carotid artery (ICA) is clamped at its origin with the guidewire placed in the external carotid artery (ECA). After primary stenting and control arteriography, CCA and ECA are clamped and the ICA clamp moved more distally. An arteriotomy is performed in the CCA, with flushing of possible debris and thrombus before performance of the eversion CEA, once again flushing before completion of the anastomosis. Follow-up ranged from 6 to 36 months with average follow-up of 22.15 ± 11.31 months.

Results: All procedures went uneventfully. Out of 18 patients, 11 were males and 7 females, mean age 66.6 ± 3.82 years. In 10 patients (55.5%), simultaneous CEA and CCA angioplasty was performed, in 7 patients (38.9%) CEA and BCT angioplasty, and in 1 patient (5.5%) tubular graft interposition between the CCA and the ICA and CCA angioplasty. In 6 patients (33.3%), CCA/BCT balloon angioplasty alone was performed simultaneously with CEA. None of the patient had postoperative transient ischemic attack, stroke, hematoma, dissection, myocardial infarction, or ischemia in the early postoperative period and during the follow-up. There were no lethal outcomes, neither in the early postoperative course nor during the follow-up.

Conclusions: Antegrade approach for simultaneous treatment of proximal CCA/BCT and distal carotid lesions with temporary ICA clamping is safe and feasible procedure that should be thought of in the future in addition to already described retrograde approach.

Conflicts of interest: None.

This study was partly funded by Serbian Ministry of Sciences and Technological Development—project number 41002.

¹Vascular Surgery Clinic, “Dedinje” Cardiovascular Institute, Belgrade, Serbia.

²School of Medicine, Belgrade University, Belgrade, Serbia.

³Clinic for Radiology, “Dedinje” Cardiovascular Institute, Belgrade, Serbia.

Correspondence to: Slobodan Tanaskovic, MD, Vascular Surgery Clinic, “Dedinje” Cardiovascular Institute, Heroja Milana Tepica 1 Street, 11000 Belgrade, Serbia; E-mails: drslobex@yahoo.com or drslobex@gmail.com

Ann Vasc Surg 2017; ■: 1–7
<http://dx.doi.org/10.1016/j.avsg.2017.05.023>

© 2017 Elsevier Inc. All rights reserved.

Manuscript received: March 28, 2017; manuscript accepted: May 7, 2017; published online: ■ ■ ■

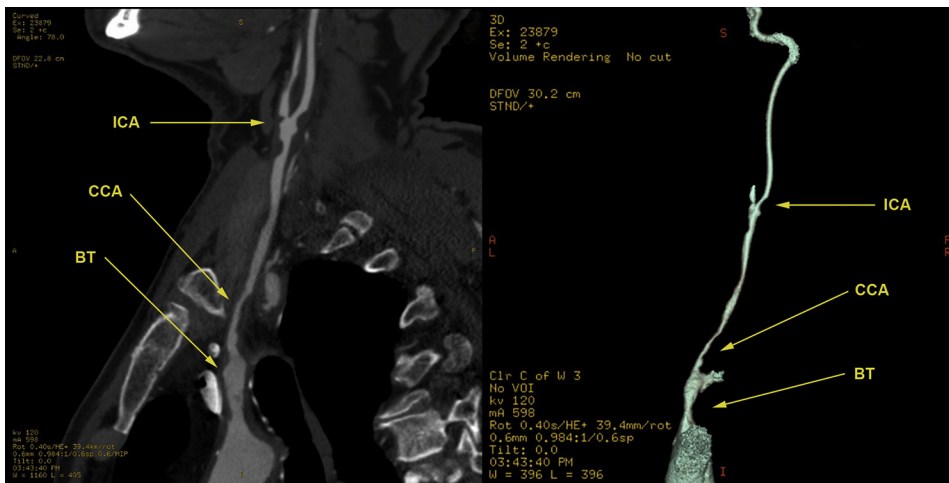


Fig. 1. Simultaneous proximal BCT/CCA and distal ICA lesions.

INTRODUCTION

The first hybrid approach for the treatment of simultaneous carotid bifurcation stenosis and proximal supraaortic arch vessel lesion was described by Dietrich et al.¹ in 1996. This technique included exposure of carotid arteries, retrograde stenting of proximal lesions followed by carotid endarterectomy (CEA). In patients with tandem stenosis of brachiocephalic trunk (BCT) or common carotid artery (CCA) and carotid bifurcation, there are always technical doubts if these lesions should be treated separately or simultaneously. Simultaneous proximal and distal lesions could be seen in less than 5% of all cases of supraaortic arch atherosclerosis, and there is general agreement that these lesions should be treated simultaneously since it is hard to tell which lesion is symptomatic.^{2,3}

With the improvement of endovascular techniques in the last 2 decades and increasing number of hybrid operating rooms, numerous studies have reported the outcome of hybrid approach, although including small series.^{4–15} All of these studies are describing retrograde approach and several technical variations, retrograde angioplasty and stenting first followed by extensive flushing, and then performance of the CEA or CEA first, followed by retrograde proximal angioplasty and stenting. In this study, we are presenting antegrade approach for the treatment of simultaneous carotid and CCA/BCT lesions in hybrid operating room that was not described previously.

METHODOLOGY

From January 2012 till January 2016, antegrade hybrid procedures were performed in 18 patients.

All the data were prospectively collected as part of our institution database. Patients were admitted to our institute for elective supraaortic arch multidetector computed tomography (CT) angiography (MDCT) according to color duplex scan findings performed earlier. After MDCT was performed, simultaneous proximal and distal supraaortic arch lesions were discovered (Figs. 1 and 2). Patients were presented to the consilium consisted of vascular surgeons and interventional radiologist, and hybrid procedures were indicated. The protocol of study and informed consent were approved by the Institutional Review Board, and all subjects gave informed consent.

Technical Details

Simultaneous procedures were performed in the hybrid operating room. All procedures were performed in the terms of general endotracheal anesthesia. First, internal carotid artery (ICA), external carotid artery (ECA), and CCA were surgically exposed and dissected. The patient is administered 100 units/kg i.v. of unfractionated heparin, a transfemoral sheath 6F or 7F is introduced into the proximal vessels, and the lesion is crossed. To cross the lesion, a hydrophilic Advantage (Terumo®, New Jersey, United States) or Storck® (Cordis, California, United States) 0.035-mm guidewires were used.

Prior to stent placement, the ICA is clamped above its origin, after distal ending of the plaque (Fig. 3) with guidewire placed in the ECA. Primary stenting is then performed without predilation, followed by angioplasty, and confirmed by control arteriography. In all cases, balloon expandable stents were used. The CCA and ECA

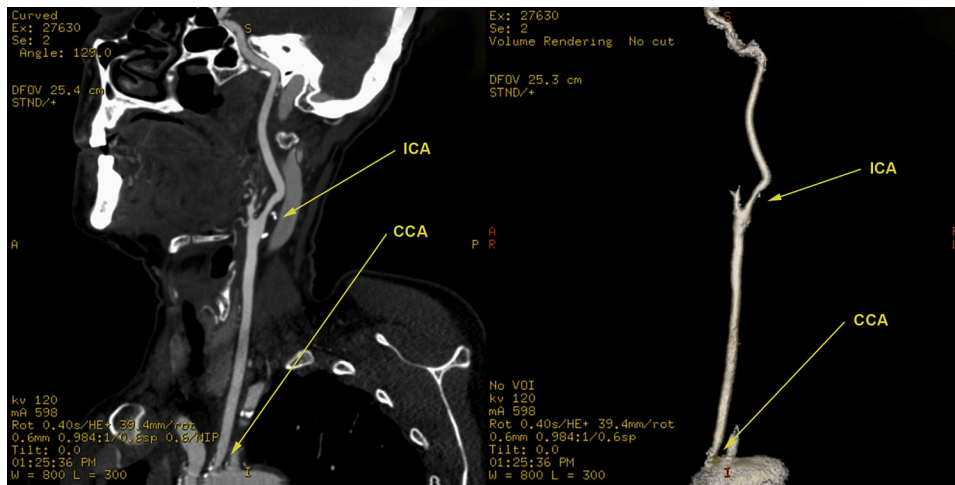


Fig. 2. Simultaneous proximal CCA and distal ICA lesions.

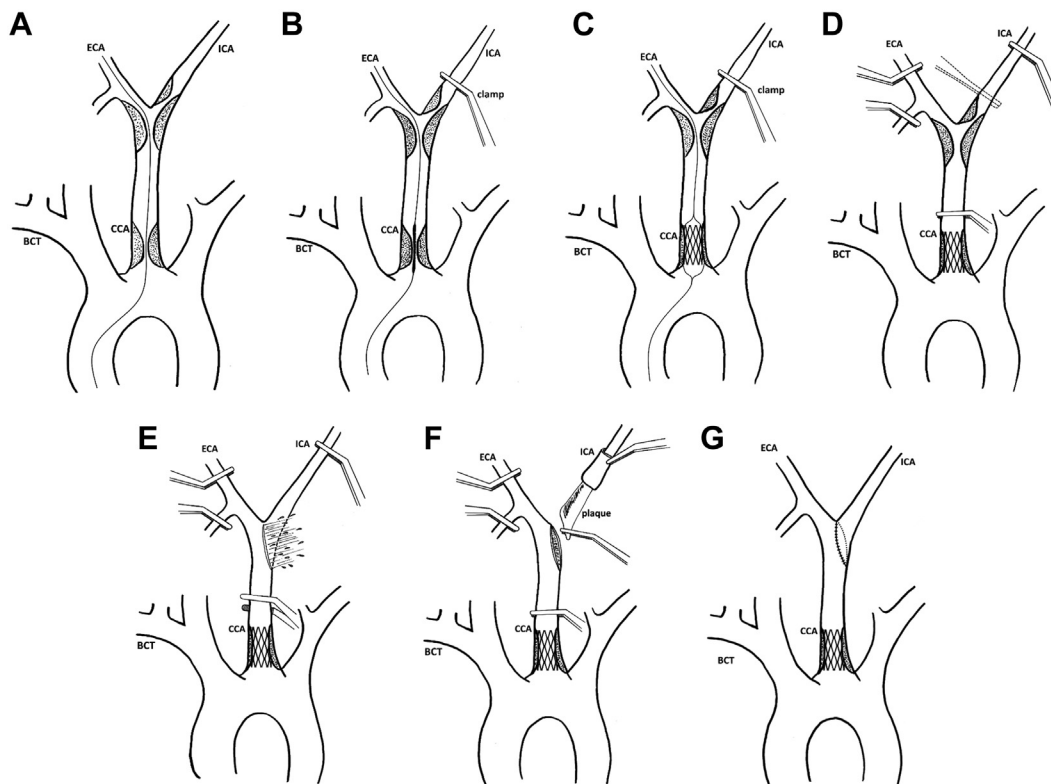


Fig. 3. Antegrade approach for simultaneous BCT/CCA angioplasty and CEA. **(A)** crossing the proximal lesion with the guidewire in the ECA; **(B)** ICA clamping just before stent placement; **(C)** expansion of the stent and control angiography; **(D)** moving ICA clamp more

distally with ECA and CCA clamping; **(E)** arteriotomy and flushing of the debris; **(F)** continuing with the eversion CEA; **(G)** the final result after CEA and proximal stenting.

are then clamped, and the ICA clamp is moved more distally. An arteriotomy is performed in the CCA, with flushing of possible debris and thrombus before performance of the eversion

CEA, once again flushing before completion of the anastomosis (Fig. 3). During the procedure, near-infrared cerebral oximetry was used for cerebral blood flow monitoring.

Table I. Demographic data and comorbidities

Demographic data and comorbidities	Number of patients (%)
Hypertension	15 (83.3)
Hyperlipidemia	16 (88.9)
Diabetes mellitus	4 (22.2)
Smoking (previous and current)	16 (88.9)
Hereditary	4 (22.2)
Previous vascular surgery	6 (33.3)
Peripheral occlusive arterial disease	7 (38.9)
Coronary artery disease	5 (27.8)
Obstructive lung disease	3 (16.7)
Previous stroke	2 (11.1)
Previous TIA	3 (16.7)
Previous myocardial infarction	5 (27.8)

After the completion of the procedure, neck wound was sutured with the placement of aspirational drainage. Patients were extubated in the operating room with immediate inspection of neurological status. In the same afternoon, patients were administered low-molecular-weight heparin (LMWH) of 0.6 mL in 1 daily dose, and in the next morning, LMWH was excluded and aspirin and clopidogrel introduced instead. Control color duplex ultrasound was performed 3 months after the procedure and then after 6 months, 1 year, and annually afterward. Follow-up ranged from 6 to 36 months with average follow-up of 22.15 ± 11.31 months.

RESULTS

Out of 18 patients, 11 were males and 7 females with mean age of 66.6 ± 3.82 years. Demographic data and comorbidities are shown in Table I. Out of 18 patients, previous stroke was seen in 2 patients (11.1%), transient ischemic attack (TIA) in 3 patients (16.7%), 3 patients (16.7%) had loss of consciousness, 7 patients (38.9%) had vertigo and walking instability, while 3 patients (16.7%) were asymptomatic. Brain CT was performed in 5 patients before the surgery: in 2 patients (40%) positive and in 3 (60%) negative for ischemia. None of the patients had associated intracranial aneurysms, abdominal aorta aneurysm, or insufficiency of the Willis circle. Associated stenosis of vertebral arteries was seen in 6 patients (33.3%) and subclavian artery in 10 patients (55.6%). The degree and characteristics of carotid, CCA, and BCT stenosis are presented in Table II. When the quality of the plaques was assessed (ICA and proximal lesions), 4 patients (22.2%) had vulnerable complicated plaques, 2 (11.1%) had soft lipid plaque, 9 patients (50%)

Table II. Characteristics of internal, common carotid and brachiocephalic trunk stenosis

Stenosis characteristics	Number of patients (%)
ICA stenosis 70–85%	7 (38.9)
ICA stenosis 85–99%	11 (61.1)
Average peak systolic velocity	432.31 ± 134.36
Average end-diastolic velocity	160.56 ± 23.10
Contralateral ICA occlusion	3 (16.7)
Contralateral ICA significant stenosis (75–95%)	3 (16.7)
Associated significant CCA stenosis (>70%)	11 (61.1)
Associated significant BCT stenosis (>70%)	7 (38.9)
Associated CCA and BCT stenosis	3 (16.7)

had fibrocalcified plaques, and 3 patients (16.7%) heterogeneous plaques. Operative details are shown in Table III.

As seen in Table III, in 1 patient, graft interposition was performed between the CCA and the ICA due to extensive lesions in the ICA and difficult distal plaque control. Other than graft interposition at the end of the procedure, surgical technique did not differ in any part from previously described. In 6 patients (33.3%), percutaneous angioplasty alone was performed simultaneously with CEA without stenting. Types of the used stents are presented in Table IV.

All patients had regular postoperative course, and none of the patient had postoperative TIA, stroke, hematoma, dissection, myocardial infarction, or ischemia in the early postoperative period and during the follow-up. Likewise, neurological mortality or mortality of other cause was not verified neither in the early postoperative course nor during the follow-up.

DISCUSSION

In the past 2 decades, numerous studies were published describing different techniques of hybrid procedures in the treatment of tandem atherosclerotic lesions of supraaortic branches.^{4–15} In all of these studies, surgeons have used retrograde approach to treat proximal lesions, and most of them have included relatively small number of patients.

The first large retrospective study, describing endovascular treatment of CCA or BCT combined with CEA by Levien et al.,² has included 44 symptomatic patients.² Simple balloon angioplasty was performed by retrograde approach through arteriotomy

Table III. Operative details and characteristic

Operative details	Number of patients (%)
CEA + CCA percutaneous angioplasty	10 (55.5)
Graft interposition + CCA percutaneous angioplasty	1 (5.5)
CEA + BCT percutaneous angioplasty	7 (38.9)
Additional ICA abbreviation	2 (11.1)
Average clamping time	11.7 ± 2.9 min
CEA + CCA/BCT percutaneous angioplasty only	6 (33.3)

of the CCA followed by forward bleeding, before commencing CEA. The angioplasty failed in 1 patient due to extensive calcifications of the BCT. After a 3-year follow-up, patency of the proximal treated lesions was 88%. The interesting fact was high mortality rate (46% after 5 years), mostly caused by coronary artery disease with authors' comment that high mortality rate was caused by more advanced atherosclerosis in these patients.

Another retrospective study of 16 patients submitted to simultaneous CEA and retrograde endovascular treatment of significant CCA or BCT stenosis by Grego et al.³ showed good results. After carotid arteries' exposure and clamping of the CCA distally to the sheath entry point, direct stenting of proximal lesions was performed. Afterward, ICA and ECA were clamped, and the arteriotomy was performed, followed by extensive flushing. The endarterectomy was then completed with the subsequent shunt placement, and the final reconstruction was done with PTFE patch closure. In 2 patients, BCT lesions could not be crossed, so these patients were converted to open surgery. There were no strokes or deaths during the whole follow-up period.

Recently, Sfyroeras et al.¹⁶ have published a meta-analysis of combined CEA and proximal balloon angioplasty for tandem stenosis of the arch vessels and carotid bifurcation in 133 patients. All analyzed papers have described retrograde approach of proximal lesions through previously exposed surgical site.¹⁶ In some papers, retrograde percutaneous angioplasty was performed first, followed by extensive flushing and then CEA, while in the others, sheath for angioplasty was introduced just before completing the suture line after the CEA followed by completion of retrograde percutaneous procedure and stenting. In all cases, carotid arteries were clamped distally to the sheath entry site to prevent embolization of the plaque' debris. In the early post-operative period, 2 strokes were reported (1 fatal),

Table IV. Types of used stents

Stent type	Number of patients (%)
None	6 (33.3)
Express LD vascular® (Boston Scientific Corporation, Natick, Massachusetts, USA)	5 (27.8)
Assurant Cobalt 8 × 20 mm® (Medtronic, Minneapolis, Minnesota, USA)	1 (5.6)
Assurant Cobalt 9 × 30 mm® (Medtronic, Minneapolis, Minnesota, USA)	1 (5.6)
Assurant 8 × 30 mm® (Medtronic, Minneapolis, Minnesota, USA)	2 (11.1)
Omnalink Duo Elite 9 × 29 mm® (Abbot vascular, California, USA)	3 (16.7)

both as a consequence of CCA occlusion, giving a 30-day mortality rate of 0.7% and 30-day stroke rate of 1.5%. During the midterm follow-up (12–36 months), high mortality rate was reported (17 patients, 12.8%) but with no precise information about the cause of the death. In addition, patients treated with direct stenting had a significantly lower restenosis rate (3 out of 79, 3.7%), than the ones treated with simple balloon angioplasty (7 out of 50, 14%). Clouse et al.⁴ have recently analyzed 23 patients who underwent simultaneous proximal endovascular interventions and carotid CEA and reported quite high complication rate including dissection (13%), stroke (9%), and death (4%).

To our knowledge, presented study is the first one to describe antegrade approach for the simultaneous treatment of proximal supraaortic arch and distal ICA lesions. In general, antegrade approach for CCA or BCT angioplasty is considered as a high-risk procedure due to distal embolization. However, by clamping the ICA just before stent deployment followed by extensive flushing afterward, we believe that embolization of the debris is completely prevented. In addition, clamping time is minimally prolonged only by the time needed for stent placement and subsequent control angiography, which takes no more than 1–2 min in most cases.

As for the procedure itself, there are several issues that could be discussed. The first is position of the clamp on the ICA just prior to proximal lesion stenting. In our study, clamp was placed above ICA origin, after distal ending of the plaque. After angioplasty of proximal lesion, clamp on the ICA is moved more distally with tweezers holding ICA while moving the clamp. By more proximal clamping, but after plaque finishing, we are safer to prevent distal embolization, still primary clamping of the distal

part of the ICA might also be good option with retrograde flow from the ICA flushing possible debris or thrombus after finishing proximal angioplasty. Primary distal ICA clamping will be considered in future. Another issue is risk of distal embolization while crossing proximal lesions without ICA clamp in place. Clamping of the ICA while crossing the proximal lesion, angiography, stent placement, and control angiography would significantly increase clamping time, so we have decided to clamp ICA just prior to stent placement with the minimal risk of crossing proximal lesions as for any isolated proximal angioplasty performed by interventional radiologists. Furthermore, all proximal lesions in presented study were 70–90% that were not that tight with high risk of embolization.

Type 3 of aortic arch is known as one of the predictors for difficult carotid stenting and prolonged fluoroscopy time,¹⁷ which was one of the reasons for retrograde approach in mentioned studies regarding hybrid procedures.¹⁶ In the presented study, there were no type 3 aortic arches, all were type 1 or type 2. In case of associated proximal and distal lesions in the presence of aortic arch type 3, we also recommend simultaneous procedure in a retrograde fashion.

Transfemoral approach, as such, carries an additional risk of major access-site complications, including inguinal hematoma and femoral artery dissection.^{18,19} However, in the presents study, no such complications were noted, and complication rate reported in other studies (from 0.8% to 2.4%) seems acceptable.^{18,19}

The use of routine or selective shunting in carotid surgery is still controversial.²⁰ In the presented study, shunt was not used and this is another issue that could be discussed. Routinely, we do not use shunt at our institute with short average clamping time²¹ and excellent overall and neurological outcome.²¹ We believe that surgeons should stick to their own policy regarding shunt use that are giving good results since recently published studies showed that intraoperative shunt use has no clinical benefit after analyzing 3,153 patients²² even in patients with contralateral carotid occlusion.²³ In the presented study, during the procedure, near-infrared cerebral oximetry was used for cerebral blood flow monitoring and there was no need for shunt in any patient.

CONCLUSION

Antegrade approach for simultaneous treatment of proximal CCA/BCT and distal carotid lesions with temporary ICA clamping is safe and feasible

procedure. This approach should be thought of in the future in addition to already described retrograde approach.

REFERENCES

1. Diethrich EB, Marx P, Wrasper R, et al. Percutaneous techniques for endoluminal carotid interventions. *J Endovasc Surg* 1996;3:182–202.
2. Levinn LJ, Benn CA, Veller MG, et al. Retrograde balloon angioplasty of brachiocephalic or common carotid artery stenoses at the time of carotid endarterectomy. *Eur J Vasc Endovasc Surg* 1998;15:521–7.
3. Grego F, Frigatti P, Lepidi S, et al. Synchronous carotid endarterectomy and retrograde endovascular treatment of brachiocephalic or common carotid artery stenosis. *Eur J Vasc Endovasc Surg* 2003;26:392–5.
4. Clouse WD, Ergul EA, Cambria RP, et al. Retrograde stenting of proximal lesions with carotid endarterectomy increases risk. *J Vasc Surg* 2016;63:1517–23.
5. Sidhu PS, Morgan MB, Walters HL, et al. Technical report: combined carotid bifurcation endarterectomy and intraoperative transluminal angioplasty of a proximal common carotid artery stenosis: an alternative to extrathoracic bypass. *Clin Radiol* 1998;53:444–7.
6. Sullivan TM, Gray BH, Bacharach JM, et al. Angioplasty and primary stenting of the subclavian, innominate, and common carotid artery in 83 patients. *J Vasc Surg* 1998;28:1059–65.
7. Macierewicz J, Armon MP, Cleveland TJ, et al. Carotid endarterectomy combined with proximal stenting for multilevel disease. *Eur J Vasc Endovasc Surg* 2000;20:572–5.
8. Arko FR, Buckley CJ, Lee SD, et al. Combined carotid endarterectomy with transluminal angioplasty and primary stenting of the supra-aortic vessels. *J Cardiovasc Surg [Torino]* 2000;41:737–42.
9. Lutz HJ, Do DD, Schroth G, et al. Hybrid therapy of symptomatic stenosis of the innominate artery. *Eur J Vasc Endovasc Surg* 2002;24:184–5.
10. Allie DE, Hebert CJ, Lirtzman MD, et al. Intraoperative innominate and common carotid intervention combined with carotid endarterectomy: a “true” endovascular surgical approach. *J Endovasc Ther* 2004;11:258–62.
11. Payne DA, Hayes PD, Bolia A, et al. Cerebral protection during open retrograde angioplasty/stenting of common carotid and innominate artery stenoses. *Br J Surg* 2006;93:187–90.
12. Peterson BG, Resnick SA, Morasch MD, et al. Aortic arch vessel stenting: a single-center experience using cerebral protection. *Arch Surg* 2006;141:560–4.
13. Bazan H, Sheahan M, Dardik A. Carotid endarterectomy with simultaneous retrograde common carotid artery stenting: technical considerations. *Catheter Cardiovasc Interv* 2008;72:1003–7.
14. Nakahara I, Higashi T, Iwamuro Y, et al. Intraoperative stenting for brachiocephalic and carotid artery stenosis. *Neurosurgery* 2010;66:876–82.
15. Karathanos C, Sfyroeras GS, Stamoulis K, et al. Hybrid procedures for the treatment of multi-focal ipsilateral internal carotid and proximal common carotid or innominate artery lesions. *VASA* 2011;40:241–5.
16. Sfyroeras GS, Karathanos C, Antoniou GA, et al. A meta-analysis of combined endarterectomy and proximal balloon angioplasty for tandem disease of the arch vessels and carotid bifurcation. *J Vasc Surg* 2011;54:534–40.

17. Madhwal S, Rajagopal V, Bhatt DL, et al. Predictors of difficult carotid stenting as determined by aortic arch angiography. *J Invasive Cardiol* 2008;20:200–4.
18. Taha MM, Sakaida H, Asakura F, et al. Access site complications with carotid angioplasty and stenting. *Surg Neurol* 2007;68:431–7.
19. Ruzsa Z, Nemes B, Pintér L, et al. A randomised comparison of transradial and transfemoral approach for carotid artery stenting: RADCAR (RADial access for CARotid artery stenting) study. *EuroIntervention* 2014;10:381–91.
20. Yip HK, Sung PH, Wu CJ, et al. Carotid stenting and endarterectomy. *Int J Cardiol* 2016;214:166–74.
21. Radak D, Tanasković S, Matić P, et al. Eversion carotid endarterectomy—our experience after 20 years of carotid surgery and 9897 carotid endarterectomy procedures. *Ann Vasc Surg* 2012;26:924–8.
22. Bennett KM, Scarborough JE, Cox MW, et al. The impact of intraoperative shunting on early neurologic outcomes after carotid endarterectomy. *J Vasc Surg* 2015;61:96–102.
23. Samson RH, Cline JL, Showalter DP, et al. Contralateral carotid artery occlusion is not a contraindication to carotid endarterectomy even if shunts are not routinely used. *J Vasc Surg* 2013;58:935–40.